

Symptomatic Childhood Uremic Pericardial Effusion: An Echocardiography Image

Al-Mosawi AJ^{1,2*}

¹Department of Pediatrics and Pediatric Psychiatry, Children Teaching Hospital of Baghdad Medical City, Iraq

²Head, Iraq Headquarter of Copernicus Scientists International Panel, Iraq

1. Abstract

Large childhood symptomatic pericardial effusion demanding pericardiocentesis and pericardial drainage is rare and symptomatic childhood uremic pericardial effusion is even rarer. The aim of this paper is to report the rare occurrence of childhood uremic symptomatic pericardial effusion. A seven-year-old boy with the most extreme form of end-stage renal disease (anuric with no renal function). The patient developed large childhood symptomatic pericardial effusion which was diagnosed by echocardiography.

2. Keywords: Uremia; Symptomatic pericardial effusion; Pericardiocentesis

3. Introduction

Large childhood symptomatic pericardial effusion demanding pericardiocentesis and pericardial drainage is rare and symptomatic childhood uremic pericardial effusion is even rarer [1,2].

De la Morena Pardo (1989) studied twelve children with symptomatic pericardial effusion and diagnosed four of them as having idiopathic pericardial effusions. Other causes of symptomatic pericardial effusions were chronic renal failure, viral infection, cardiac surgery, juvenile rheumatoid arthritis and chronic myelocytic leukemia [1]. Guven et al. studied 10 (6 male, 4 female) children (mean age: 8.05 year \pm 4.4 year) large symptomatic pericardial effusion needing

pericardiocentesis and pericardial drainage. They found three patients had tuberculosis, one patient had uremic pericarditis; one patient had bacterial pericarditis; one patient had post-pericardiotomy syndrome; two patients had malignancy and two patients had no identifiable cause. Guven et al. suggested that tuberculosis is the most important cause of large symptomatic pericardial effusion particularly in the developing countries [2].

4. Patients and Methods

A seven-year-old boy with the most extreme form of end-stage renal disease (anuric with no renal function). The patient developed large childhood symptomatic pericardial effusion which was diagnosed by echocardiography (Figure 1) demanding pericardiocentesis and pericardial drainage during treatment with intermittent peritoneal dialysis and conservative medical treatment (low protein diet and fluid restriction). He was treated with peritoneal dialysis sessions intermittently whenever became symptomatic with marked nausea, tachypnea (acidotic breathing) and generalized edema from fluid overload.

5. Discussion

Uremic pericarditis without pericardial effusion was

***Corresponding author:** Al-Mosawi AJ, Department of Pediatrics and Pediatric Psychiatry, Children Teaching Hospital of Baghdad Medical City, Iraq, E-mail: almosawiAJ@yahoo.com

Received Date: August 26, 2020; **Accepted Date:** September 02, 2020;

Published Date: September 04, 2020

during the 1950s and 1960s.

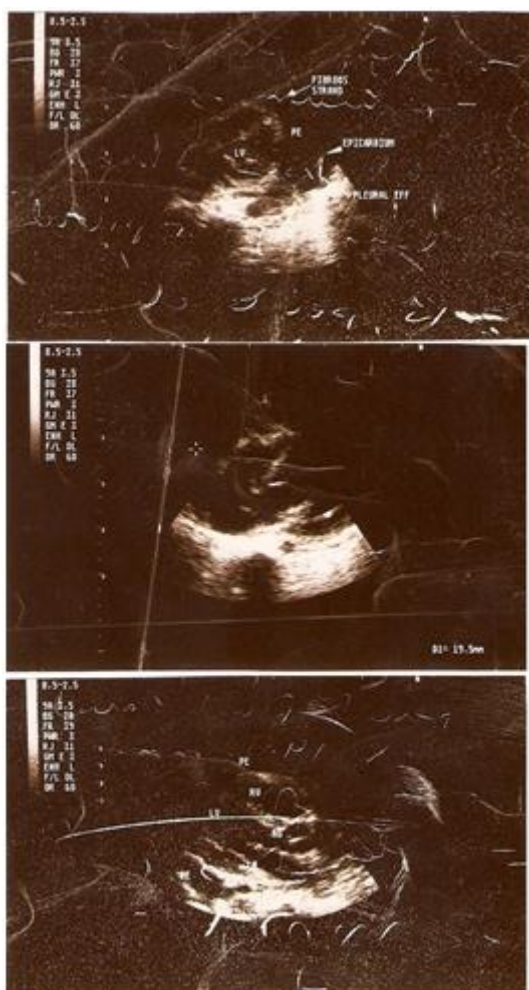


Figure 1: A seven-year-old boy with the most extreme form of end-stage renal disease (anuric with no renal function). The patient developed large childhood symptomatic pericardial effusion which was diagnosed by echocardiography.

It generally the result of an aseptic inflammation associated with fibrin formation and little or no fluid [3-5]. The occurrence of large symptomatic uremic pericardial effusion was rarely reported in adult's patients during the 1950s and 1960s [3, 6-10]. Fishberg reported the occurrence of considerable serous or haemorrhagic effusion [3].

Goodner and Brown reported the deaths of two young male patients with chronic renal disease because of large symptomatic uremic pericardial effusion. Post-mortem studies of the two patients revealed 800 ml and 850 ml of blood-stained fluid were present in the pericardial cavities [6].

Lowry and Boyd studied 227 cases of uremic pericarditis and found 58 patients with

hydropericardium and 3 with massive hemopericardium [10].

Rappaport reported the occurrence of large symptomatic uremic pericardial effusion in a ten-year-old girl.

Large symptomatic uremic pericardial effusion is a very rare condition during childhood [11-13].

6. Conclusion

This paper documented the rare occurrence of large symptomatic uremic pericardial effusion requiring drainage during childhood.

References

1. [Morena Pardo de la ML, Chamorro Romero MI, Prados Bueno R, de Inocencio Arocena J, Maroto Alvaro E, García Fernández EJ. Derrames pericárdicos sintomáticos en la edad pediátrica \[Symptomatic pericardial effusions in childhood\]. An Esp Pediatr. 1989; 31: 528-532.](#)
2. [Guven H, Bakiler AR, Ulger Z, Iseri B, Kozan M, Dorak C. Evaluation of children with a large pericardial effusion and cardiac tamponade. Acta Cardiol. 2007; 62: 129-133.](#)
3. [Fishberg AM. Hypertension and Nephritis, 5th ed. Bailliere, Tyndall and Cox. London. 1954.](#)
4. [Wardener de HE. The kidney, 2nd ed. Churchill, London. 1961.](#)
5. [Wood PH. Diseases of the heart and circulation, 2nd ed. Eyre and Spottiswoode, London. 1961.](#)
6. [Brown H, Goodner CJ. Report of two cases of cardiac tamponade in uremic pericarditis. J Am Med Assoc. 1956; 162: 1459-1461.](#)
7. [Guild WR, Bray G, Merrill JP. Hemopericardium with cardiac tamponade in chronic uremia. N Engl J Med. 1957; 257: 230-231.](#)
8. [Hutt MP, Holme S JH. Pericardial effusion complicating acute tubular necrosis. Arch Intern Med. 1961; 108: 226-230.](#)
9. [Merikas G, Samartzis M, Marketos S. Massive cardiac tamponade in uremic pericarditis with complete recovery. N Engl J Med. 1962; 266: 1089-1091.](#)

10. [Lowy AC, Boyd LJ. Some clinical aspects of uremic pericarditis. Exp Med Surg 1960; 18: 90-97.](#)
11. [Rappaport HR. Uremic pericarditis and tamponade in a ten-year-old girl. J Mt Sinai Hosp N Y. 1962; 29: 334-338.](#)
12. [Al-Mosawi AJ. The etiology of chronic renal failure in 54 Iraqi children. Pediatr Nephrol. 2002; 17: 463-464.](#)
13. [Al-Mosawi AJ. Chronic renal failure in Iraqi children: 14 year experience of a single center. J Nephro Ren Trans \(JNRT\) 2008; 1: 32-40.](#)

Citation: Al-Mosawi AJ. Symptomatic Childhood Uremic Pericardial Effusion: An Echocardiography Image. SunKrist Heart Failure Cardiol Insights. 2020; 2: 1003.

Copy Right: © 2020 Al-Mosawi AJ. This is an open-access article distributed under the terms of the Creative Commons Attribution License, which permits unrestricted use, distribution and reproduction in any medium, provided the original author and source are credited.